

# Second Opinion Report

PATIENT NAME: [REDACTED]

LOCAL TREATING PHYSICIAN NAME: [REDACTED]

CLEVELAND CLINIC CONSULTING PHYSICIAN NAME: Suneel Kamath, MD

Date: [REDACTED]

Thank you for requesting a virtual second opinion. It was our pleasure to review this case.

**In this document you will find:**

1. A summary of steps taken during case review
2. Information on the Cleveland Clinic consulting physician who reviewed the case
3. A case summary including any questions raised during intake
4. Recommendations by the consulting physician
5. Additional references / information regarding the patient's medical condition, if applicable

The consulting physician who has been carefully matched to this case has reviewed all of the information received and prepared in the medical record.

Sincerely,

The Clinic by Cleveland Clinic Care Team

## 1. Summary of Steps Taken During Case Review

Here are the **steps that took place** during your patient's case review process:

### **Live Intake with a Care Manager**

All pertinent medical background information has been collected during intake.

### **Records Collection**

Our clinical care team thoughtfully collected and prepared pertinent medical records for review by the Cleveland Clinic consulting physician.

### **Physician matching and review**

Our nurse care manager worked with our Chief Clinical Officer to match this case with a Cleveland Clinic consulting specialist. The specialist then reviewed all of the collected information and pertinent medical records to prepare this second opinion report.

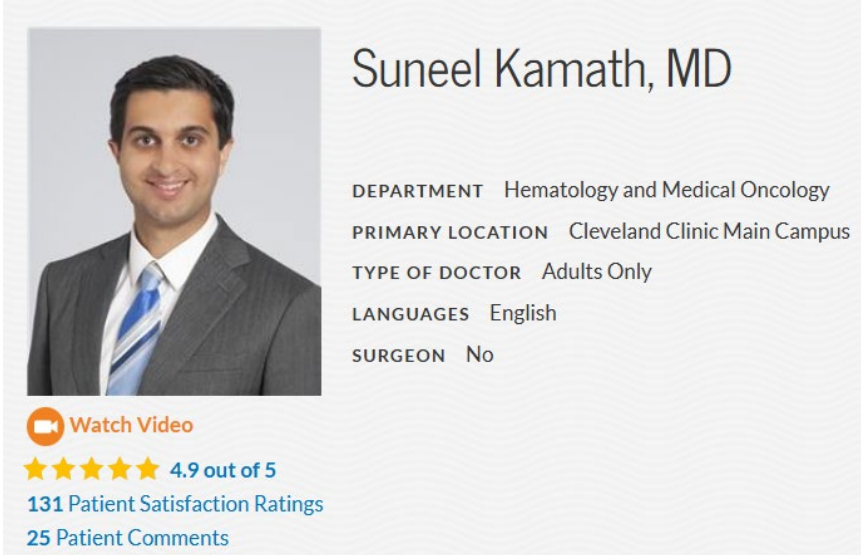
### **Written second opinion report**

This report has been prepared to share the recommendations by the reviewing physician.

## 2. Information on the physician who reviewed this case


Our clinical care team and our Chief Clinical Officer worked diligently to identify the best specialist for this case. Through this collaborative process, we matched the second opinion request with Dr. Suneel Kamath, see biography link provided below.

<https://my.clevelandclinic.org/staff/25034-suneel-kamath#biography>



**Suneel Kamath, MD**

DEPARTMENT Hematology and Medical Oncology  
PRIMARY LOCATION Cleveland Clinic Main Campus  
TYPE OF DOCTOR Adults Only  
LANGUAGES English  
SURGEON No

 Watch Video

★★★★★ 4.9 out of 5  
131 Patient Satisfaction Ratings  
25 Patient Comments

### 3. Case Summary:

Patient Name: [REDACTED]

Date of Birth: [REDACTED]

MRN: [REDACTED]

1. Is chemotherapy the next appropriate step?
2. Are there any additional treatment options to consider?

### 4. Recommendations

Thank you for the opportunity to provide you with a virtual second opinion. Our clinical team has completed a full review of the pertinent medical records for this case in context of the questions and concerns shared during intake.

#### My recommendations are as follows:

I am reviewing a 55-year-old female for a second opinion regarding best treatment for metastatic pancreatic adenocarcinoma. All history and data were obtained by review of provided medical records and imaging. She initially presented with a pancreatic tail mass found on imaging for other reasons. She underwent EUS and biopsy, which showed adenocarcinoma. Staging imaging showed the FDG-avid pancreatic tail mass invading the stomach and spleen as well as peritoneal carcinomatosis and a questionable cystic liver lesion (looked concerning for metastasis on MRI, but was not FDG-avid on PET despite being large enough to be detected by PET). She was started on gemcitabine and abraxane, has received 2-3 cycles, and subsequent imaging shows overall stable disease. She has had issues with neutropenia, thrombocytopenia requiring dose delays and addition of G-CSF.

#### **AJCC Staging:**

Cancer Staging Pancreatic adenocarcinoma Staging form: Exocrine Pancreas, AJCC 8th Edition

Clinical: Stage IV (cT4, cN1, cM1)

#### **Review of Labs:**

Outside CBC, CMP reviewed.

CA 19-9 387; 725: most recent: 429

#### **Recent Imaging:**

##### **CT Chest:**

No lung metastases or metastatic lymphadenopathy.

##### **CT pancreas:**

3.7 cm pancreatic tail mass with invasion of the spleen. Peritoneal seeding nodules noted in the pelvis. Hepatic cysts in both liver lobes.

**PET:**

FDG avid pancreatic tail mass with gastric and splenic invasion. Few foci of uptake in pelvic cavity with peritoneal infiltrations suspicious for carcinomatosis.

**MR pancreas:**

4.1 cm pancreatic tail mass with invasion into stomach and spleen. Definite metastasis in segment 4 and distant lymph nodes suspicious for metastatic disease.

**CTAP:**

4.2 x 3.7 x 2.9 cm mass in tail of pancreas. Multiple hepatic cysts, cannot exclude liver metastases.

**Pathology:**

EUS FNA pancreas tail: Poorly differentiated adenocarcinoma

**Recommendations:**

I agree with the chemotherapy regimen you are receiving (gemcitabine and abraxane given every other week instead of 3 weeks on, one week off, which will help with the blood count issues) and with adding Neulasta to the regimen to keep your white blood cells high enough. While your scans don't show much shrinkage of the tumor, everything looks stable, and the fact that the CA 19-9 tumor marker improved from 725 to 429 is a good sign that the chemo is doing something. I would continue this chemo regimen until your scans show that the tumors are growing significantly or there is a major increase in the CA 19-9 tumor marker from the blood.

If or when this current chemo regimen stops working, we have 2 options: a 3-drug regimen called FOLFIRINOX or a 2-drug regimen of 5-FU and liposomal irinotecan. The 3-drug regimen has a lot of side effects and also tends to lower the blood counts a lot, but it has a higher chance of shrinking the tumors, so you and your doctor will have to decide between the 2 regimens based on how your blood counts are doing and how you are feeling. At your age, we want to be aggressive with chemo, so FOLFIRINOX may be the better option, but if your blood counts continue to be low with your current chemo, we may have to use the 2-drug combination of 5-FU and liposomal irinotecan.

Would recommend your doctors send your pancreatic biopsy specimen for a broad panel of genetic testing (we call it next generation sequencing) to see if there are any genetic changes to your tumor that can be targeted with novel therapies.

Would recommend you get blood testing for 2 separate types of genetic testing. One is for something called germline genetic testing, which is to see if there is any hereditary reason you developed this pancreatic cancer at such a young age and to see if you and/or your family members are at risk for pancreatic cancer and other types of cancer. This testing might also identify a mutation called BRCA or a BRCA-related mutation that would make you eligible to receive a drug called olaparib at

some point in the future. The second genetic testing that should be done from the blood is for something called circulating tumor DNA. These are genetic changes that are made by your tumor, but can be detected in the blood. Most often the tumor genetic testing recommended above finds these genetic changes, but sometimes they are only found in the blood and not from the tumor testing, so it can be helpful to do both.

Thank you,  
Dr. Kamath

**5. Additional references / information regarding your patient's medical condition, if applicable**

It is important to consider clinical trials as a way to get access to novel therapies. We have one clinical trial at Cleveland Clinic that I think you would be eligible for. Clinical trials do mean traveling to the center that is running the study and receiving all of your treatments physically at that center, so if there is a large cancer center that does a lot of research near where you live, I would start there and see if they have a study you could enroll into for your 2<sup>nd</sup>- or 3<sup>rd</sup>-line treatment.

It was our pleasure to provide a second opinion on this case. If you have additional questions, please feel free to contact our care team.

Sincerely,

The Clinic by Cleveland Clinic Care Team